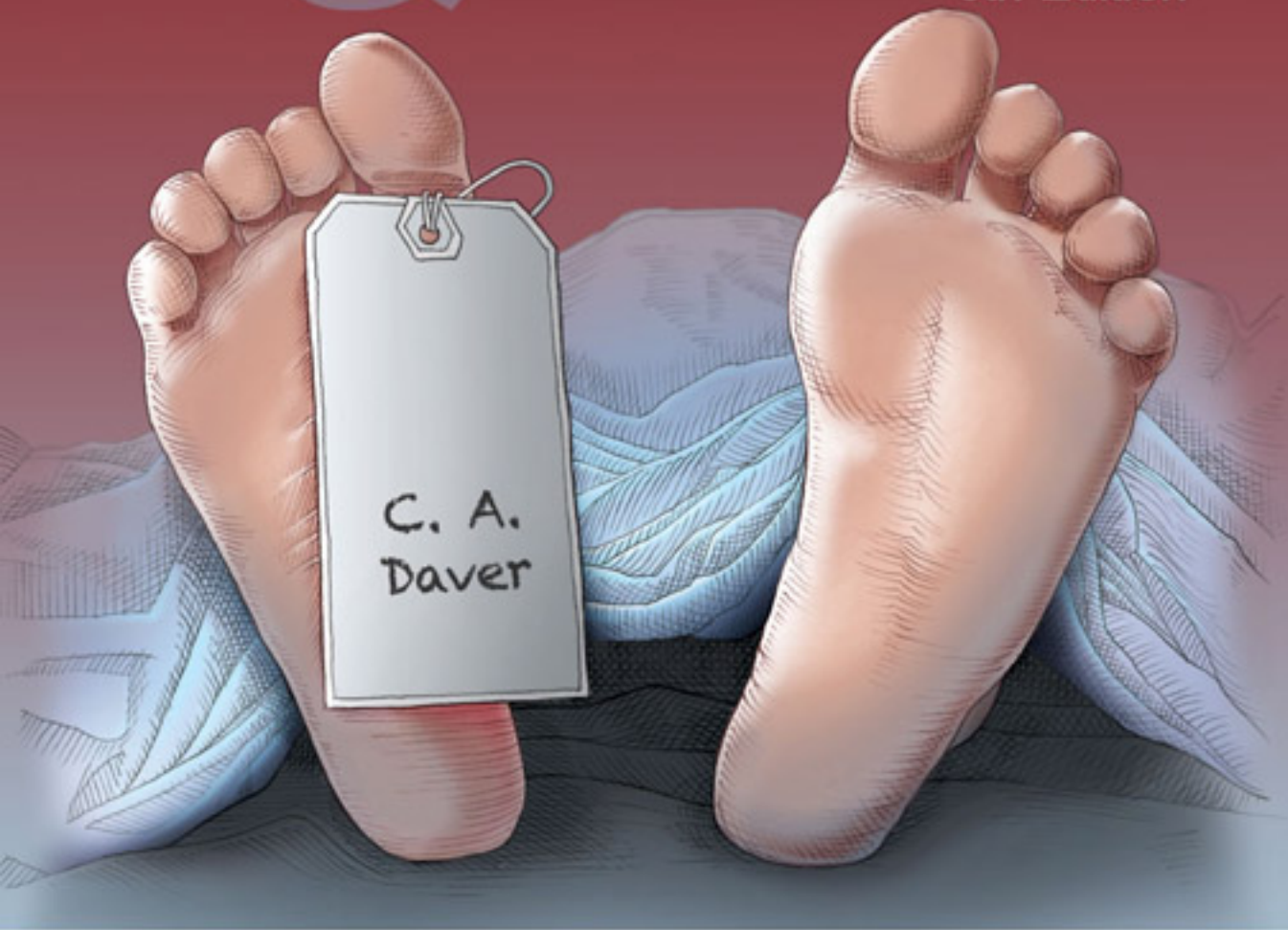




DOCTORS IN TRAINING

**GROSS
ANATOMY
& RADIOLOGY**

8th Edition



Brian Jenkins, MD

Doctors In Training: Gross Anatomy & Radiology, 2010 edition

Author: Brian Jenkins, MD

Editor: Rachel Miller, MPAS, PA-C

The author and editor disclaim any liability, loss, injury, or damage incurred as a consequence, directly or indirectly, of the use and application of any of the contents of this book. Although the information in this text has been carefully reviewed for correctness, the author and editor cannot accept any responsibility for any errors or omissions that may be made. The information contained in this publication should not be construed as specific instructions for individual patients. Manufacturers' product information and package inserts should be reviewed for current information, including contraindications, dosages, and precautions.

For problems, questions, or concerns, you may contact the author at support@doctorsintraining.com

Copyright © 2010 Doctors In Training.com, LLC
www.doctorsintraining.com

Doctors In Training.com
1701 River Run, Suite #703
Fort Worth, TX 76017

All Rights Reserved. This book is protected by copyright. No part of this book may be reproduced in any form or by any means, including photocopying, or utilized by any storage and retrieval system, without written permission from the copyright owner.

first edition, 2000
second edition, 2001
third edition, 2002
fourth edition, 2003
fifth edition, 2004
sixth edition, 2005
seventh edition, 2008
eighth edition, 2010

Preface

- This book has been structured in question/answer format because I have found that students learn best by being quizzed. Although this book may be used effectively by covering the answers and quizzing yourself, I highly recommend finding a partner to study with so that you may quiz each other.
- This book is not a replacement for lectures, labs, and small group learning sessions. This book is merely intended to be one of your best resources, not your only resource. Your performance will suffer if you do not attend lectures, labs, and group learning sessions.
- I have made references in this book to *Netter's Atlas of Human Anatomy, 5th ed.* and *Essential Clinical Anatomy, 3rd ed.* (ECA). I believe that being able to put a mental picture to what you are studying is the best way to study. These are references to relevant pictures/charts/diagrams that you will find helpful. I highly recommend that you use them.
- You will learn an enormous amount of information during your Anatomy class. You may want some tips as to how you can get the most out of your study time. Here are some tips that I found useful:
 - Before lecture and lab, know the anatomy. Use Netter's along with this study guide and/or your lab dissector to identify structures you should know. If you go to class without first gaining familiarity with the structures, then you will be lost.
 - If you cannot identify the anatomy in Netter's, then you will not be able to identify it in lab.
 - Take notes in your Netter's during lecture. Simply highlighting a structure you should know is much quicker than trying to write it down. Additionally, when you review your lecture notes you won't have to keep switching back and forth from your notes to your atlas.
 - Go to lecture, labs, group learning sessions, and review sessions.
 - Use Harrison's, Stat-Ref!, or Up-To-Date for self learning issues. If you don't know about these resources, ask a friend or talk to a librarian.
- Don't think that you can memorize structures one day and remember them three days later. Sometimes it takes a few days to completely memorize and retain something. Remember to review throughout the course. This is the perfect resource for a quick review in this course, in another course, or for the USMLE.
- Know that for anatomy lab, you must know all of the bold terms in the pages covered in your anatomy dissector.
- If there are any errors in this study guide, please let us know at support@doctorsintraining.com as soon as possible.

Doctors In Training

Gross Anatomy & Radiology Study Guide

Table of Contents

1	Anatomical Terminology	5
2	Intro. to Radiology	5
3	Anterior Chest Wall	7
4	Pleural Cavity and Lungs	10
5	Heart and Great Vessels	13
6	Radiology: Mediastinum and Pleural Cavity	17
7	Medical Terms You Need To Know	19
8	Development and Malformations of the Heart	21
9	Back and Spinal Cord	24
10	Radiology: Spine	27
11	Shoulder and Deltoid	28
12	Brachial Plexus and Nerves of the Upper Extremity	30
13	Radiology: Brachial Plexus	32
14	Axillary Artery and its Branches	32
15	Which nerves run with the following arteries?	33
16	Forearm	33
17	Which nerve is damaged...? (upper extremity)	36
18	Which muscles perform the following actions?	36
19	Which nerve is damaged...? (hand, wrist, and forearm)	36
20	Which nerves innervate the following muscles?	37
21	Hand and Wrist	38
22	Radiology: Forearm and Wrist	39
23	Joints of the Upper Extremity	40
24	Anterior Abdominal Wall	41
25	Scrotum, Spermatic Cord, and Testis	43
26	General Disposition of Gut and Great Vessels	45
27	GI Tract	48
28	Radiology: GI Tract	51
29	Liver, Gall Bladder, and Pancreas	52
30	Radiology: Upper Abdomen	55
31	Spleen, Diaphragm, and Posterior Wall	57
32	Kidneys, Ureters, and Adrenal Glands	59
33	Radiology: Retroperitoneum	61
34	GI Embryology and the Abdomen Nervous System	62
35	Anterior and Posterior Triangles of the Neck and Cervical Viscera	65
36	The 12 Cranial Nerves	69
37	Thyroid Gland, Face, Parotid Region, and Infratemporal Region	68
38	Radiology: Head and Neck (Normal and Abnormal)	74

Doctors In Training Gross Anatomy & Radiology Study Guide

Table of Contents (continued)

39	Scalp, Cranium, Cranial Cavity, and Brain	74
40	Which cranial nerve is responsible for communicating the following information?	78
41	Where does the following cranial nerve exit the skull?	79
42	Radiology: Brain (Normal and Abnormal)	80
43	Embryology of Neck and Face	82
44	From which pharyngeal arch did the following structures arise?	84
45	Orbit and Eyeball	85
46	CV Joint, Skull Base, and Retropharyngeal Space	88
47	Pharynx, Nasal Cavity, and Oral Cavity	89
48	Larynx	93
49	Ear	94
50	General Pelvic Structures and Female Pelvic Viscera	96
51	Ischiorectofossa, Perineum, Nerves and Vessels	99
52	Male Pelvic Viscera, Bladder, and Lymphatics	103
53	Radiology: Pelvis	105
54	Embryology of Pelvis	106
55	Which muscles are responsible for the following actions of the hip and knee?	108
56	Which muscles do the following nerves of the hip and thigh innervate?	108
57	Gluteal Region and Thigh	109
58	Which muscles do the following nerves of the leg innervate?	112
59	Which muscles are responsible for the following actions of the foot and toes?	112
60	Leg and Foot	113
61	Joints of the Lower Extremity	115
62	Radiology: Lower Extremity	117

Guide to page references

Netter's = Atlas of Human Anatomy, 5th ed. (2011) by Frank H. Netter
ECA = Essential Clinical Anatomy, 3rd ed. (2007) by Keith Moore and Anne Agur

Chapters 1 & 2 are not included in this preview.

3 - Anterior Chest Wall

Netter's: Bony Framework of Thorax p179
 Anterior Thoracic Wall p182-184
 Topography of Lungs: Anterior View p190

1. What are the 3 segments of the sternum?

manubrium, body, and xiphoid process

- **What is the name of the location where the manubrium and the body of the sternum meet?**

sternal angle (angle of Louis)

- **The costal cartilage of which rib articulates at the sternal angle?**

2nd

2. Which rib articulates at the xiphoid-sternal junction?

7th

3. Where does the nipple lie on males?

4th intercostal space (midclavicular line)

4. Where is the 2nd intercostal space located? Where is the subcostal space located?

All intercostal spaces lay below the rib. (e.g., 2nd intercostal space is below the 2nd rib)
 The subcostal space is found below the 12th rib.

5. At which rib level does the internal thoracic (internal mammary) artery bifurcate. Which 2 arteries are formed at this bifurcation?

- rib 6
- superior epigastric and musculophrenic arteries

6. Where are the following imaginary lines found?

midsternal line	from jugular notch, through the middle of the sternum, to the xiphoid process
midclavicular line	midpoint of the clavicle
anterioaxillary line	where pectoralis major meets the axilla (armpit)
midaxillary line	midpoint of axilla (armpit)
posteroaxillary line	where latissimus dorsi meets the axilla

7. What are the 4 spinal curvatures, and when do they develop?

Thoracic and sacral curvatures are seen at birth.

Cervical curvature develops after the baby begins to lift its head

Lumbar curvature develops when the baby stands and begins to walk. (ECA p272)

8. What are the 3 categories of ribs, and which ribs belong to each category?

- vertebrocostal (true) ribs 1-7 attach directly to sternum
- vertebrochondral (false) ribs 8-10 attach to cartilage of the rib directly above
- vertebral (floating, free) ribs 11-12 no anterior attachment

9. True or False? The lungs end at the first rib.

False, the lungs continue above the first rib.

10. What is flail chest?

Paradoxical (opposite of normal) movement of anterior and lateral chest with breathing due to multiple rib fractures

(ECA p52)

11. What can be found in the costal groove of a rib in order from superior to inferior?

VAN- vein, artery, nerve

- **When inserting a needle into the chest (thoracocentesis), is it best to insert above or below the rib?**

Inserting above the rib insures that you will not damage the VAN found on the inferior surface of the rib. (ECA p72)

- **Between what muscles can the VAN be found?**

between the innermost and internal intercostal muscles

12. What do Langer's lines represent?

lines of tension of collagen underneath the skin

- **Is heavy scarring more or less likely to occur if an incision is made perpendicular to Langer's lines?**

more likely (It is best to make an incision parallel to Langer's lines.)

Netter's: Mammary Gland, Arteries of, and Lymph p176-178

13. What are the four quadrants of the breast?

upper medial, lower medial, upper lateral (and axillary tail), lower lateral (ECA p60)

14. Is breast located in superficial or deep fascia?

superficial fascia

- **What is the name given to the region between the mammary glands and the deep fascia?**

retromammary space

- **What anchors the breast to the superficial fascia?**

Suspensory Ligaments of Cooper

15. What is the function of the Glands of Montgomery found on the areola of the breast?

lubrication to prevent chaffing and irritation (esp. during pregnancy and breast feeding)

16. How many lactiferous ducts can be found in the nipple?

15-20

17. To where does the majority of lymphatic fluid drain from the breast?

- axillary lymph nodes (>75% drains here) ← lateral breast
- internal thoracic (parasternal) nodes ← medial breast
- to the opposite breast ← medial breast
- abdominal (inferior phrenic) nodes ← inferior breast

- **Why is it important to understand where lymph drains?**

Cancer metastasis frequently follows lymph drainage.

18. Which arteries supply the breast?

- internal thoracic (internal mammary) artery (including anterior intercostal artery branches)
- posterior intercostal arteries
- lateral thoracic artery

- **Which artery provides the chief blood supply to the breast?**

internal thoracic artery (AKA internal mammary artery)

19. What is the meaning of the terms polymastia, polythelia, and gynecomastia?

polymastia - extra breast(s)

polythelia - extra nipple(s)

gynecomastia - male breasts

20. Along what line do the breast/nipples develop?

embryonic mammary ridge (AKA milk line)

21. What are 4 physical findings in advanced breast cancer, and what do they indicate?

- increased vascularity = increased blood supply to area → excessive growth and nutrient use
- orange peel (peau d'orange) = edema and thickened skin → lymph node involvement/blockage
- dimpling = suspensory ligament involvement
- nipple retraction / bleeding = lactiferous duct involvement (ECA p60)

- **True or false? Nipple retraction is always a sign of breast cancer.**

false

- **How many patients presenting with a bloody discharge from the nipple will have breast cancer?**

about 1 in 10

22. In which quadrant is breast cancer most commonly found?

upper outer quadrant

- **As a result, where can most breast cancer metastasis be found?**

axillary nodes

- **What does the term "sentinel lymph node" mean?**

The first lymph gland that drains the tumor . cancer spreads from tumor to here first

23. True or false? Breast cancer can occur in both males and females.

True, about 1.5% of breast cancers occur in men.

Muscles of Anterior Chest Wall**24. What is the origin, insertion, action, and nerve supply of the pectoralis major?**

O: clavicle, sternum, costal cartilage of ribs

I: humerus

A: adduction, medial rotation, flexion

NS: lateral and medial pectoral nerves from the brachial plexus

25. What is the origin, insertion, action, and nerve supply of the pectoralis minor?

O: ribs 3-5

I: coracoid process

A: scapula forward, raises ribs in forced inspiration

NS: medial pectoral nerve

- **Which nerve pierces the pectoralis minor muscle?**

medial pectoral nerve

26. What is the origin, insertion, action, and nerve supply of the serratus anterior?

O: ribs 1-8

I: vertebral border of scapula

A: prevents scapula winging, abducts arm above 90 degrees (ECA p420)

NS: long thoracic nerve

27. Which muscles originate on ribs 3-6 and help keep the internal thoracic (internal mammary) artery and vein down on the anterior chest plate?

transverse thoracis muscles

28. What are the intercostal muscles, and what are their actions?

external - inspiration

(Netter's p183)

internal - expiration

innermost - expiration

(hint: in-muscles give expiration, ex-muscles give inspiration)

- **In which direction do the external and internal intercostal muscles run?**

external- from lateral to medial going down (same direction as your hand in your pocket)

internal- from medial to lateral going down (same direction as your hand touching your face)

Chapters 3 through 62 are not included in this preview.

FIND OUT WHAT'S

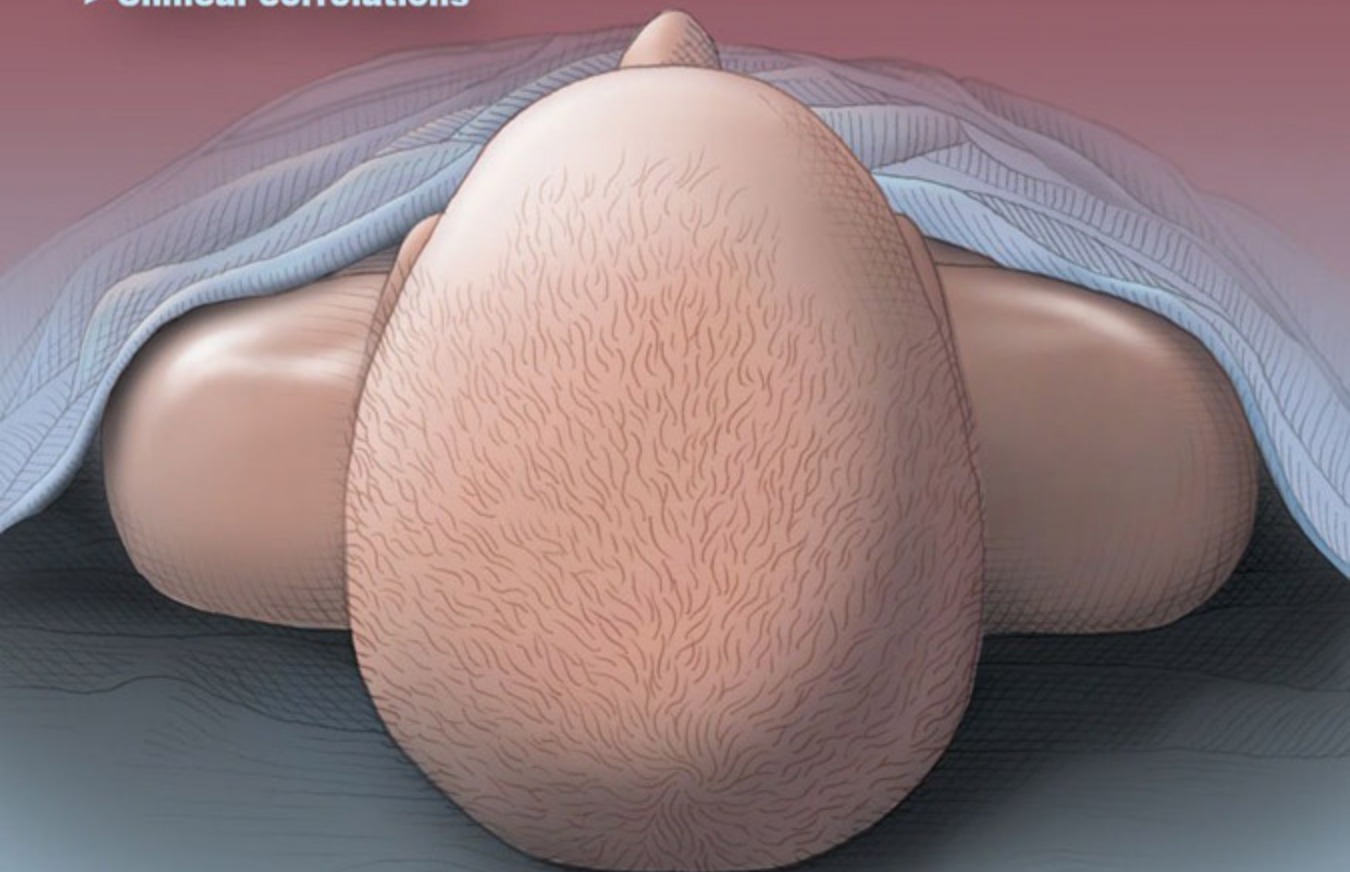


- > **Anatomy terminology**
- > **Anatomy by system**
- > **Nerves & vessels**
- > **Muscle actions**
- > **Embryologic derivations**
- > **Radiologic views**
- > **Clinical correlations**

A study guide packed full of the high-yield points you need to know to ace anatomy

Short answer and self-quiz format to help you learn more

A perfect partner to your Netter's Atlas of Human Anatomy and clinical anatomy textbooks



DOCTORS IN TRAINING